

Cystoid Macular Edema

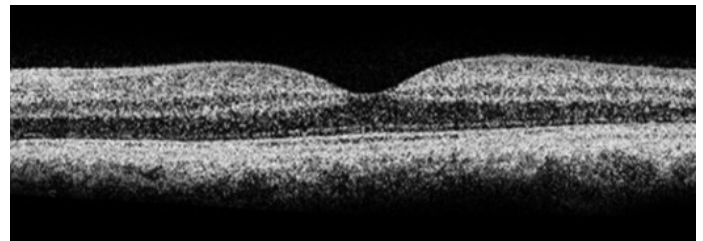
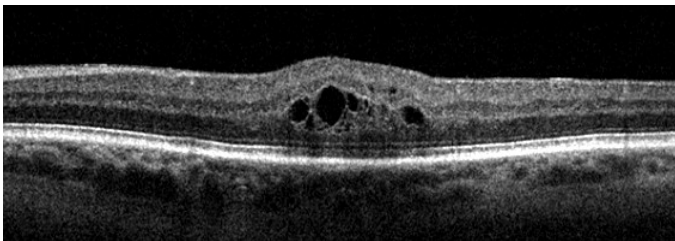
Cystoid macular edema (CME) refers to swelling of the central part of the retina (the macula). The retina is like the film in a camera, and the macula is responsible for detailed central vision. When the macula experiences swelling (edema), central vision is reduced.

What causes cystoid macular edema?

CME can occur for a variety of reasons. Cystoid macular edema can accompany inflammation in the eye after ocular surgery (such as cataract surgery) or it can occur after blockage of a retinal vein (branch retinal vein occlusion or central retinal vein occlusion). Primary inflammatory disorders of the eye (uveitis) can cause CME. Wet age-related macular degeneration can cause CME, although other findings such as bleeding and fluid under the retina are usually seen as well. Macular edema can occur in diabetic patients due to leaky blood vessels, in which case the term “diabetic macular edema” is used. CME can occur from mechanical traction on the macula, as in the case of an epiretinal membrane. Less common causes of CME include retinitis pigmentosa, cancer in the eye, and radiation. CME is rarely seen as a side effect of medications such as niacin (used to treat high cholesterol).

How is cystoid macular edema diagnosed?

Like many conditions, cystoid macular edema can range from mild to severe. In most cases, CME is visible during detailed examination of the macula by an eye specialist. Additional testing is often indicated to determine the cause and severity of CME. Common tests include optical coherence tomography (OCT) and fluorescein angiography (FA). OCT is a non-invasive scan of the retina which measures the degree of swelling and shows your doctor a cross section of the swollen area.



▲ Cross-sectional optical coherence tomography (OCT) image of a retina swollen centrally with cystoid macular edema (left) compared to a normal retina without swelling (right).

BayAreaRetinaAssociates

Diseases and Surgery of the Retina and Vitreous



800-5-RETINA (800-573-8462)

<http://www.bayarearetina.com>

Allen Verne MD | Craig Leong MD | Stewart Daniels MD | Subhramsu Ray MD, PhD | Daniel Ting MD, PhD | Tushar Ranchod MD | Roger Goldberg MD, MBA

ANTIOCH

CASTRO VALLEY

FREMONT

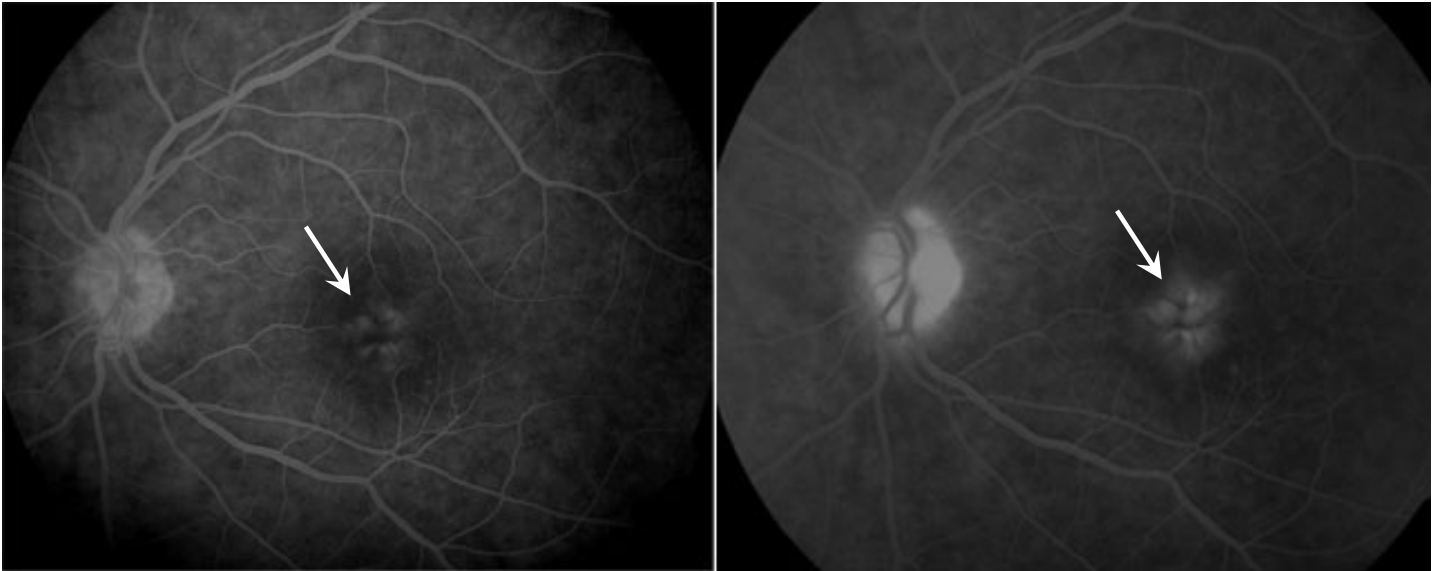
OAKLAND

PLEASANTON

SAN LEANDRO

VALLEJO

WALNUT CREEK



▲ Fluorescein angiography showing cystoid macular edema, seen as increasing petalloid leakage (arrows).

Fluorescein angiography involves a small intravenous injection of dye (fluorescein) followed by a series of photographs of the retina. The images show blood flow and any leakage from blood vessels in the retina, and the patterns seen in these images are often necessary to diagnose the cause of cystoid macular edema.

How is cystoid macular edema treated?

The treatment of CME depends on the underlying cause. In some cases, such as after cataract surgery, eye drops may be an appropriate first treatment. In many cases, swelling is reduced by an injection of medicine into the eye after the eye is numbed. Several different medicines can be injected into the eye depending on the cause of CME, and your retina specialist will discuss these options in detail if such treatment is deemed appropriate. In some diseases, such as branch retinal vein occlusion or diabetic macular edema, the treatment regimen may include one or more sessions of laser. If an epiretinal membrane is pulling on the retina and causing CME, surgery may be recommended to remove the membrane. Surgery is sometimes recommended in other conditions as well depending on the response to first line therapies.

BayAreaRetinaAssociates

Diseases and Surgery of the Retina and Vitreous



800-5-RETINA (800-573-8462)

<http://www.bayarearetina.com>

Allen Verne MD | Craig Leong MD | Stewart Daniels MD | Subhransu Ray MD, PhD | Daniel Ting MD, PhD | Tushar Ranchod MD | Roger Goldberg MD, MBA

ANTIOCH CASTRO VALLEY FREMONT OAKLAND PLEASANTON SAN LEANDRO VALLEJO WALNUT CREEK

Bay Area Retina Associates is a group practice of retinal surgeons. All members of the group are board certified by the American Academy of Ophthalmology and have completed fellowship training in vitreoretinal surgery. BARA surgeons have expertise in the treatment of retinal detachment, diabetic retinopathy, age-related macular degeneration, macular hole, epiretinal membrane, and retinal vascular disease. BARA physicians see patients in eight offices and perform surgery at several hospitals and surgery centers around the East Bay.